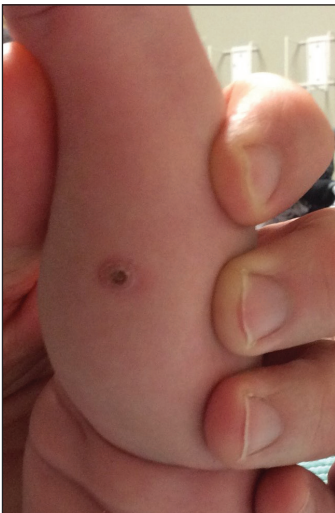

# Yellow-Brown Ulcerated Papule in a Newborn

Tia M. Pyle, MD; Warren R. Heymann, MD

## Eligible for 1 MOC SA Credit From the ABD

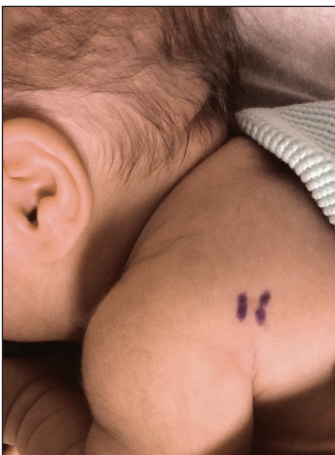This Photo Challenge in our print edition is eligible for 1 self-assessment credit for Maintenance of Certification from the American Board of Dermatology (ABD). After completing this activity, diplomates can visit the ABD website (<http://www.abderm.org>) to self-report the credits under the activity title "Cutis Photo Challenge." You may report the credit after each activity is completed or after accumulating multiple credits.



An 18-day-old infant boy presented with yellow-brown ulcerated papules on the left posterior leg (top) and left posterior shoulder (bottom). He was born via spontaneous vaginal delivery at 33 <sup>1</sup>/<sub>7</sub> weeks' gestation complicated by preeclampsia. The lesions were unchanged during the infant's stay in the neonatal intensive care unit. However, his mother noted that one lesion crusted once home without an increase in size. His fraternal twin sister did not have any similar lesions. Jaundice and hepatosplenomegaly were absent. He was referred to hematology/oncology. A complete blood cell count revealed nonconcerning slight anemia. Liver function tests, coagulation studies, a chest radiograph, and a skeletal survey were ordered.

## WHAT'S THE DIAGNOSIS?

- congenital self-healing reticulohistiocytosis
- juvenile xanthogranuloma
- leukemia cutis
- nummular eczema
- urticaria pigmentosa



PLEASE TURN TO **PAGE 275** FOR THE DIAGNOSIS

From the Division of Dermatology, Cooper Medical School of Rowan University, Camden, New Jersey.

The authors report no conflict of interest.

Correspondence: Tia M. Pyle, MD, Division of Dermatology, Cooper Medical School of Rowan University, 3 Cooper Plaza, Ste 504, Camden, NJ 08103 (Tia.m.pyle@gmail.com).

## THE DIAGNOSIS:

# Congenital Self-healing Reticulohistiocytosis

**B**iopsy of a representative lesion from this patient was consistent with congenital self-healing reticulohistiocytosis, as shown in the Figure. Characteristic Langerhans cells were present in the dermis that stained CD1a positive, S-100 positive, and CD68 negative to confirm the diagnosis.

Congenital self-healing reticulohistiocytosis, or Hashimoto-Pritzker syndrome, is a rare benign form of Langerhans cell histiocytosis. It is twice as common in males than females and typically noted at birth or early during the neonatal period. Lesions may present as pink, firm, asymptomatic papulonodular lesions that often ulcerate with possible residual hypopigmentation or hyperpigmentation.<sup>1</sup> The differential diagnosis includes congenital infectious and hematologic diseases typically associated with blueberry muffin baby. Thus, varicella, cytomegalovirus, syphilis, toxoplasmosis, rubella, neuroblastoma, leukemia cutis, and extramedullary hematopoiesis, among others, may be considered. Juvenile xanthogranuloma or urticaria pigmentosa also enter the differential diagnosis given the yellow-brown appearance. As a clonal

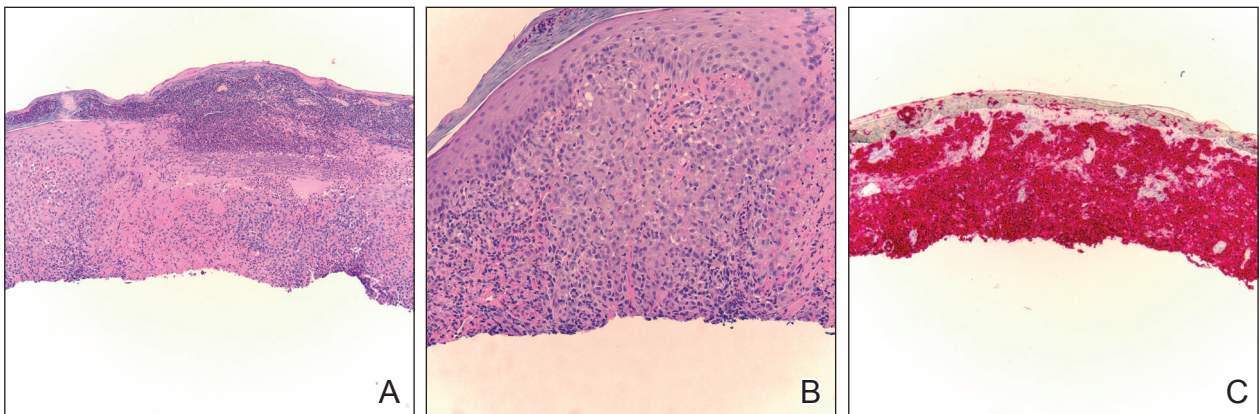
proliferation of Langerhans cells, pathology reveals lesions that stain positive for CD1a and S-100.<sup>2</sup>

Although typically absent, evaluation for systemic involvement is warranted, which may be an early presentation of multisystem Langerhans cell histiocytosis. Continued monitoring is recommended given the risk of relapse and associated mortality. Our patient continues to do well. He will continue to be followed by our team and hematology/oncology during early childhood.

The treatment of congenital self-healing reticulohistiocytosis may include conservative monitoring, topical steroids, topical nitrogen mustard, tacrolimus, or psoralen plus UVA.<sup>3</sup> Surgical excision may be considered for large lesions.

### REFERENCES

1. Parimi LR, You J, Hong L, et al. Congenital self-healing reticulohistiocytosis with spontaneous regression. *An Bras Dermatol*. 2017;92:553-555.
2. Chen AJ, Jarrett P, Macfarlane S. Congenital self-healing reticulohistiocytosis: the need for investigation. *Australas J Dermatol*. 2016;57:76-77.
3. Gothwal S, Gupta AK, Choudhary R. Congenital self healing Langerhans cell histiocytosis. *Indian J Pediatr*. 2018;85:316-317.



A, The surface of a nodular collection of uniform Langerhans cells was present in the dermis that was CD1a positive, S-100 positive, and CD68 negative (H&E, original magnification  $\times 10$ ). B, Beneath an ulcer was a dense dermal infiltrate of uniform Langerhans cells that was CD1a positive, S-100 positive, and CD68 negative (H&E, original magnification  $\times 20$ ). C, Lesion that stained positive for CD1a (original magnification  $\times 10$ ).